TRANSVERSE MYELITIS FOLLOWING SARS-COV-2 VACCINATION: A CASE REPORT

MIELITE TRANSVERSA APÓS VACINAÇÃO CONTRA SARS-COV-2: RELATO DE CASO

Emyr Hiago Bellaver
ORCID 0000-0002-7169-1000
Universidade Alto Vale do Rio do Peixe, UNIARP
Caçador, Brasil
hi.agobellaver@hotmail.com

Débora Santos Souza
ORCID 0009-0002-8509-7712
Universidade do Alto Vale do Rio do Peixe, UNIARP
Caçador, Brasil
deebby.ss@outlook.com

Paula Carolina Kath
ORCID 0009-0003-0189-9927
Universidade do Alto Vale do Rio do Peixe,
UNIARP
Caçador, Brasil
bmdpaulack@gmail.com

Abstract. Acute transverse myelitis is a neuromedullary and autonomic disorder clinically characterized by motor and sensory dysfunctions below the level of spinal cord injury, resulting in significant neurological impairment. This condition has several etiologies, with infectious causes and rare post-vaccination reactions being the most relevant. This report presents a case study of transverse myelitis following SARS-CoV-2 vaccination in a patient from a city in southern Brazil. The study is a descriptive and retrospective case report. Reporting such a case is pertinent when it involves rare diagnoses, pioneering treatments, or unexpected outcomes in otherwise conventional scenarios. The case was defined based on clinical signs and symptoms, along with diagnostic tests that supported the diagnosis of transverse myelitis after SARS-CoV-2 immunization. Given the scarcity of studies and case reports on this condition in the context of vaccination, the present report is highly relevant to the medical and scientific community, as its findings may support accurate diagnosis in similar future cases.

Keywords: *Myelitis1; Spinal Cord Inflammation2; Postvaccinal Myelitis3; COVID-19 Vaccines4; ChAdOx1 nCoV-195;*

Resumo. A mielite transversa aguda é uma doença neuromedular e autonômica clinicamente caracterizada por disfunções motoras e sensoriais abaixo do nível da lesão medular, resultando em comprometimento neurológico significativo. Essa condição possui diversas etiologias, sendo as causas infecciosas e as raras reações pós-vacinais as mais relevantes. Este relato apresenta um estudo de caso de mielite transversa após vacinação contra SARS-CoV-2 em um paciente de uma cidade do sul do Brasil. O estudo é um relato de caso descritivo e retrospectivo. Relatar um caso como esse é pertinente quando se trata de diagnósticos raros, tratamentos pioneiros ou desfechos inesperados em cenários convencionais. O caso foi definido com base nos sinais e sintomas clínicos, juntamente com testes diagnósticos que corroboraram o diagnóstico de mielite transversa após imunização contra SARS-CoV-2. Dada a escassez de estudos e relatos de caso sobre essa condição no contexto da vacinação, o presente relato é de alta relevância para a comunidade médica e científica, pois seus achados podem auxiliar no diagnóstico preciso em casos futuros semelhantes.

Palavras-chave: *Mielite1; Inflamação da Medula Espinhal2; Mielite Pós-Vacinal3; Vacinas COVID-194; ChAdOx1 nCoV-195;*

1. INTRODUCTION

Spinal cord injuries are known to reduce quality of life and increase mortality rates, imposing significant burdens on public healthcare systems. These injuries can occur at various anatomical levels along the spinal cord, presenting either chronic or acute manifestations and

a wide range of severity (Martins & Kashiwabara, 2020; Transverse Myelitis in Children and Adults, 2023).

Acute transverse myelitis (ATM), also referred to as acute transverse myelopathy, is a neuromedullary and autonomic disorder considered a subtype of inflammatory conditions characterized by focal spinal cord inflammation and subsequent neuronal injury. This leads to neurological deficits across the transverse plane of the spinal cord, affecting both ascending and descending pathways of the central nervous system. Although the exact etiopathogenesis of ATM remains unclear, it is believed to be closely associated with dysregulated immune mechanisms (Rodríguez et al., 2018; Román et al., 2021).

Clinically, the condition is marked by motor and sensory dysfunctions below the level of the spinal cord lesion, often accompanied by severe pain. Disease progression and prognosis vary significantly, influenced by factors such as age, ethnicity, sex, and medical history (Athayde et al., 2021).

Approximately 1.8 million individuals are affected by this condition worldwide each year, with peak incidence reported between 20 and 40 years of age. Although considered rare, ATM can result in serious neurological consequences, with up to two-thirds of patients experiencing moderate to severe residual disability (Naeem et al., 2022).

During the most critical phase of the COVID-19 pandemic, the emergency approval and large-scale distribution of vaccines were essential public health measures to contain viral spread and reduce mortality (Nicola et al., 2020). While vaccination played a pivotal role in mitigating the impact of the pandemic, rare neurological adverse events were reported globally following the administration of some COVID-19 vaccines, including cases of transverse myelitis. Although these events are rare when compared to the total number of doses administered worldwide, they have prompted growing scientific interest in understanding the underlying mechanisms and developing appropriate management strategies (Nguyen et al., 2022).

The pathophysiological mechanisms of transverse myelitis remain largely unknown. However, the condition is known to occur following infections or, more rarely, as a complication of vaccination (Tahir et al., 2021). Current evidence suggests that its pathogenesis involves focal infiltration of immune cells, such as monocytes and lymphocytes, resulting in varying degrees of demyelination, axonal damage, astroglial injury, and inappropriate activation of microglia. Given that transverse myelitis has been reported after systemic infections and immunizations, the literature strongly supports a possible link with molecular mimicry and the exacerbation of autoantibodies, which may contribute to its neurological manifestations (Li et al., 2022).

Diagnosis is based on clinical spinal cord syndromes supported by imaging findings, with magnetic resonance imaging (MRI) being the preferred tool for both evaluation and documentation. Clinical symptoms generally correlate with MRI findings and with evidence of inflammatory processes affecting the central nervous system (Transverse Myelitis in Children and Adults, 2023). There is currently no standardized treatment protocol for transverse myelitis, as therapeutic approaches must be individualized according to both intrinsic and extrinsic patient-specific factors (Frohman & Wingerchuk, 2010).

Given these considerations, this study aims to report a case of transverse myelitis following COVID-19 vaccination in a municipality located in the south-central region of Brazil.

2. METHODS

This is a descriptive case report involving a 37-year-old male patient from the central-western region of Santa Catarina, southern Brazil, currently under medical and laboratory follow-up. The study was conducted following a review of the literature on transverse myelitis, detailed documentation of the case, and a narrative discussion based on findings from scientific

databases. Ethical approval was granted by the Human Research Ethics Committee under protocol CAAE: 6.077.653. The patient provided written informed consent, including authorization for the use of clinical images, with all ethical standards and confidentiality fully observed.

3. RESULTS

The patient is a 37-year-old white male, married, residing in a municipality in the midwestern region of Santa Catarina, Brazil. He had a medical history of hypertension and type 2 Diabetes mellitus, with no other known comorbidities. At the time of the presentation, he was conscious, oriented in time and space, and reported no previous contact with SARS-CoV-2. He received the AstraZeneca/FIOCRUZ COVID-19 vaccine (lot number 216VCD187Z) on July 23, 2021.

On September 9, 2021, while following his usual routine and seated for lunch, the patient suddenly experienced a headache and sharp spinal pain, described as lancinating. This was followed by pronounced paresthesia in both upper and lower limbs, which rapidly progressed to global motor areflexia. He required immediate assistance from others to prevent a fall and was taken to the emergency department of a hospital located in the mountainous region of Santa Catarina, where he received initial medical care and underwent neurological and imaging evaluations. He also reported having experienced a recent episode of fever.

The patient was hospitalized for 31 days in the same regional hospital and received various treatments, including high-dose corticosteroid pulse therapy, neuromuscular blocks, continuous opioid administration, ketamine, and other supportive therapies aimed at controlling pain and neurological symptoms. At a certain point, the attending neurologist considered a potential association between the patient's neurological condition and his recent SARS-CoV-2 vaccination. Further diagnostic investigations were conducted, including brain and spinal cord neuroimaging (Figure 1), blood tests, and cerebrospinal fluid analysis.

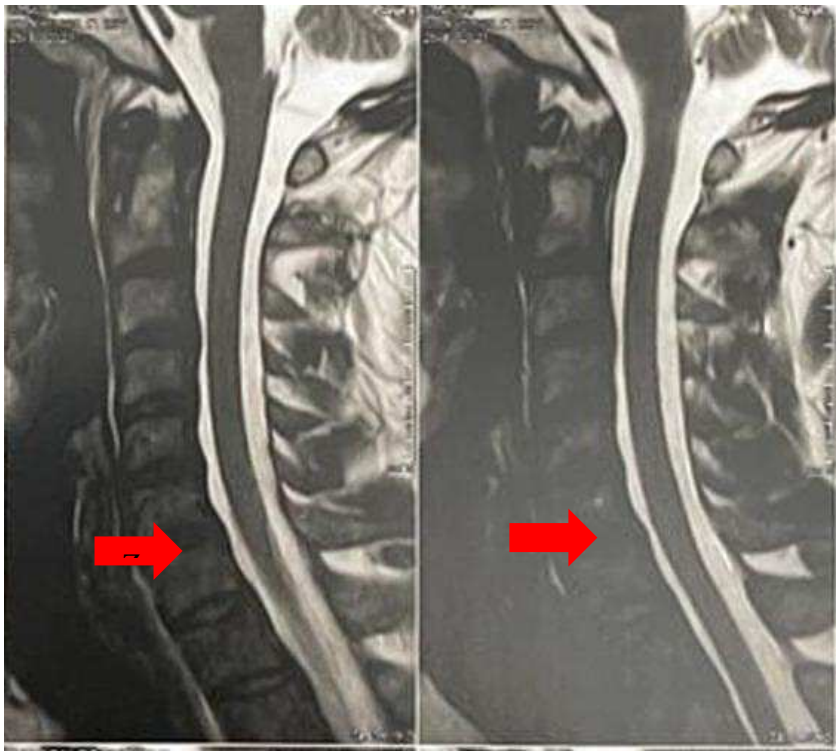

Figure 1. Sagittal view of magnetic resonance imaging (MRI) of the thoracic spinal cord. Patient's medical record.

Magnetic resonance imaging (MRI) of the cervical spine performed on October 25, 2021, revealed straightening of the physiological cervical curvature, cervical discopathy with disc protrusions at multiple levels, and an area of intraspinal signal alteration at the C6–C7 level, affecting the central and left lateral portions of the spinal cord. A mild and heterogeneous enhancement was observed after contrast administration, suggestive of an inflammatory or infectious process (myelitis). Arrows indicate signal changes in the posterior portion of the cervical spinal cord at the C6–C7 level, consistent with transverse myelitis.

Following symptom onset, the patient did not report significant improvement over several days and continued to experience persistent pain. In the subsequent weeks, his condition worsened, requiring rehospitalization for 11 days at a coastal hospital in the state of Santa Catarina. During this period, he presented with severe headache, cervical pain, and red flag signs following the previously described acute episode. Upon clinical evaluation, the patient exhibited left-sided hemiparesis, muscle weakness in the pelvic and shoulder girdles, arthralgia in the metacarpophalangeal joints, two previous episodes of fever, hypokinesia, globally increased reflexes with bilateral Tromner and Hoffmann signs, bilateral sustained ankle clonus, and a plantar flexor response.

Table 1. Comparison of signs and symptoms of transverse myelitis described in the literature with those presented by the patient in this case.

Signs and symptoms described in the literature	Signs and symptoms presented by the patient
Intramedullary spinal cord signal alteration	✓
Inflammatory/infectious changes in the spinal cord	✓
Gait disturbances	✓
Cerebrospinal fluid (CSF) alterations	✓
Arthralgia	✓
Ataxia	✓
Absence of bacterial growth in CSF	✓
Painful crises in lower limbs	✓
Hypokinesia	✓
Spastic paralysis	✓
Paresis and paresthesia of the lower limbs	✓

Source: Authors (2025)

Medical reports from specialists in rheumatology, neurology, psychiatry, and orthopedics confirmed the diagnosis of post-vaccination transverse myelitis associated with intractable chronic pain and paraparesis, with a Modified Rankin Scale score of 2, resulting in permanent disability for the patient (see supporting documents).

Regarding treatment, the patient underwent pulse therapy with intravenous methylprednisolone at a dose of 250 mg over 5 minutes for 5 consecutive days, with no adverse events, leading to temporary pain relief. He was also prescribed duloxetine 30 mg, with plans to increase to 60 mg depending on clinical evolution, along with opioid analgesia including intravenous administration of 10 mg morphine and 50 mg pethidine. Additional complementary therapies were implemented, such as acupuncture, hydrotherapy, and physical therapy.

Despite temporary pain relief, the patient consistently reports a daily pain level of 7–8 out of 10. During acute pain crises reaching a level of 10, the patient requires immediate emergency care to receive appropriate opioid analgesia.

Currently, the patient is on a regimen that includes Dorene Tabs (pregabalin) 150 mg, methadone 10 mg, Oxypinal 20 mg, morphine 20 mg, Dolantin (pethidine) 50 mg, and 10 mg

morphine patches, while still requiring emergency care for severe breakthrough pain. He reports a persistent daily pain level ranging from 7 to 10 (Table 2).

Table 2. Temporal evolution of clinical manifestations and biochemical and serological tests for case follow-up.

Month/Year	Primary Event	Outcome	Report/Findings
07/2021	Immunization	No complications	During this post-vaccination period, the patient did not report any perceptible changes in the first few days.
09/2021	Symptom onset	Initial symptoms observed	Headache, stabbing neck pain, paresthesia in upper and lower limbs.
10/2021	Laboratory and imaging investigations	Initial biochemical, hematological, and imaging tests	Cervical MRI: Cervical discopathy with disc protrusions at several levels; signal alteration in the C6–C7 spinal cord affecting central and left lateral portions, with discrete and heterogeneous contrast enhancement, suggestive of an inflammatory/infectious process (transverse myelitis). Serological blood test: No significant abnormalities observed.
10/2021	New hematological and biochemical tests	Lumbar puncture	Alterations in oligoclonal bands; CSF glucose: 45.69 mg/dL; CSF protein: 92.017 mg/dL; no bacterial growth; WBC: 15/mm³; mononuclear cells present.
07/2022	Medical consultation	Medical certificate	The patient's condition has progressively worsened month after month, with poor clinical prognosis and limited prospects of treatment efficacy for pain control and/or disease recovery. He was referred for multidisciplinary care, including neuroimmunology, physical therapy, psychology, and psychiatry.
2023	Medical consultation	Medical certificate	With evidence of progressive deterioration, the patient continues to experience increasingly intense and persistent pain. The prognosis has worsened, with some specialists suggesting a limited life expectancy of only a few months. Nevertheless, the patient was advised to continue follow-up with a specialist in Pain Management and Rehabilitation.

Source: Authors (2025)

4. DISCUSSION

In the present case, the clinical and radiological findings showed a remarkable similarity to those described in the literature, reinforcing the diagnostic hypothesis of post-vaccination transverse myelitis.

Although further studies are needed to fully understand the underlying pathophysiology, the similarities observed between this case and previously reported ones may be attributed to

the significant neuromedullary involvement associated with the disease. This includes focal collections of inflammatory cells, varying degrees of demyelination, axonal and astroglial damage, and intramedullary microglial activation. As a result, the neuroanatomical dysfunction caused by TM affects the ascending and descending spinal pathways transversely, leading to motor, sensory, and autonomic impairments. These clinical manifestations often correspond to specific dermatomes at the level of the spinal lesion (Román et al., 2021; Naeem et al., 2022; Loz et al., 2022).

The clinical presentation, laboratory tests, and imaging findings in this case support the diagnosis of post-vaccination transverse myelitis, especially given the absence of other etiologies to explain the patient's condition. Spinal cord alterations observed in magnetic resonance imaging (MRI) after symptom onset, along with cerebrospinal fluid (CSF) analysis, oligoclonal band detection, and abnormal biochemical findings in blood tests, reinforce this diagnosis (Li et al., 2022; Khan et al., 2022).

Furthermore, no evidence of bacterial growth was found, nor were there positive Gram stains, aquaporin antibodies, or any other pathogens or pre-existing conditions that could justify the neurological symptoms. The only vaccine administered to the patient during the period of symptom onset was the SARS-CoV-2 vaccine. This, in conjunction with similar cases described in various parts of the world, supports a potential association between the COVID-19 vaccine and the development of transverse myelitis (Mărginean et al., 2022).

Neurological complications have been associated with vaccines since the 1880s. Given that TM has been reported following systemic infections or immunizations, the literature suggests a potential relationship with molecular mimicry and the exacerbation of autoantibodies, which may contribute to the onset of the disease. Although the exact pathophysiology of post-vaccination TM is not yet fully understood, it is believed that the initial inflammatory cascade in such cases may result from an exaggerated humoral response triggered by recognition of the viral protein encoded by SARS-CoV-2. When uncontrolled, this immune response may lead to harmful neurological consequences rather than protection (Khan et al., 2022; Van Doremalen et al., 2020).

In this context, the vaccine used in this case relies on a recombinant chimpanzee adenoviral vector encoding the structural spike protein (nCoV-19) of SARS-CoV-2. This vector functions as an immune adjuvant and triggers the recruitment of interleukins such as IL-6 and IL-17. These immune mediators stimulate cytokine production and attract additional inflammatory cells, which may lead to autoimmune hyperreactivity and, through various mechanisms, result in spinal cord injury (Román et al., 2021).

Regarding the risk-benefit ratio of COVID-19 vaccination, there are still no comprehensive statistics on the incidence of transverse myelitis as a vaccine-related adverse event. However, the AstraZeneca vaccine reference document described a temporally associated case as early as March 2021. Since then, additional case reports have emerged in the literature, gradually increasing awareness of this potential association (Román et al., 2021; Li et al., 2022; Khan et al., 2022).

Nevertheless, despite the possibility of adverse events related to vaccines, particularly those for COVID-19, their benefits are unequivocal. Vaccination has played a critical role in controlling the pandemic, significantly reducing morbidity and mortality worldwide (Wahid et al., 2023). Outside the emergency context, further studies are expected to provide better understanding and control of rare adverse effects, contributing to even safer and more effective immunization strategies.

5. CONCLUSION

In summary, acute transverse myelitis is characterized by sensory disturbances and pain, along with blood–brain barrier alterations, the presence of IgG in the cerebrospinal fluid, and

magnetic resonance imaging abnormalities, all of which constitute strong indicators of this neurological condition. Although current statistics regarding the development of transverse myelitis following COVID-19 vaccination remain limited, case reports are gradually emerging in the literature.

Regarding therapeutic approaches, various strategies are currently employed, including corticosteroids, plasma exchange, cyclophosphamide, immunomodulators, and novel therapies, although clinical outcomes are not always satisfactory. Moreover, providing ongoing physiotherapeutic, psychological, and educational support is essential to assist the patient in fully reintegrating into society and coping with the challenges imposed by this condition.

As new studies and case reports continue to be published, the scientific understanding of the relationship between acute transverse myelitis and vaccines is expected to expand, offering new insights and improved clinical management.

CONFLICT OF INTEREST

The authors declare that the research was conducted in the absence of any commercial or financial relationships that could be construed as a potential conflict of interest.

SUPPLEMENTARY MATERIAL

Supplementary materials are provided in a separate file attached to this document.

DATA AVAILABILITY STATEMENT

The data used in this study were voluntarily provided by the patient, who granted permission for their use and sharing, provided that no personal information or identifying details would be disclosed. All data presented complies with the ethical consent obtained from the participant and follow current regulations on the use of human data in research.

REFERENCES

Athayde, V. H. F. M., Lima, T. M. D. A. B., Andrade, G. M., Arruda, D. R. D., Ribeiro, M. M., Gonçalves, J. S., et al. (2021). Mielite transversa aguda: Repercussões clínicas e atualidades / Acute transverse myelitis: Clinical repercussions and current affairs. *Brazilian Journal of Health Review, 4*(6), 29174–29190.

Frohman, E. M., & Wingerchuk, D. M. (2010). Transverse myelitis. *New England Journal of Medicine, 363*(6), 564–572.

Khan, E., Shrestha, A. K., Colantonio, M. A., Liberio, R. N., & Sriwastava, S. (2022). Acute transverse myelitis following SARS-CoV-2 vaccination: A case report and review of literature. *Journal of Neurology, 269*(3), 1121–1132.

Li, X., Raventós, B., Roel, E., Pistillo, A., Martinez-Hernandez, E., Delmestri, A., et al. (2022). Association between COVID-19 vaccination, SARS-CoV-2 infection, and risk of immune-mediated neurological events: Population-based cohort and self-controlled case series analysis. *BMJ,* e068373. https://doi.org/10.1136/bmj-2021-068373

Loz, S. H., Da Silva, G. F., Da Silva, C. F., Oliveira, R. E. N. D. N., Silva, F. W. D., Baptista, J. P. R., et al. (2022). Mielite transversa e vacina COVID-19: Uma associação temporal. *Brazilian Journal of Infectious Diseases, 26,* 101803.

Mărginean, C. O., Meliț, L. E., Cucuiet, M. T., Cucuiet, M., Rațiu, M., & Săsăran, M. O. (2022). COVID-19 vaccine—A potential trigger for MOGAD transverse myelitis in a teenager—A case report and a review of the literature. *Children, 9*(5), 674. https://doi.org/10.3390/children9050674

Martins, L. R., & Kashiwabara, T. G. B. (2020). Mielite transversa aguda: Revisão de literatura. *Brazilian Journal of Surgery and Clinical Research, 30*, 89–94.

Naeem, F. N., Hasan, S. F. S., Ram, M. D., Waseem, S., Ahmed, S. H., & Shaikh, T. G. (2022). The association between SARS-CoV-2 vaccines and transverse myelitis: A review. *Annals of Medicine and Surgery, 79.* https://doi.org/10.1016/j.amsu.2022.103870

Nguyen, S., Bastien, E., Chretien, B., Sassier, M., Defer, G., Nehme, A., et al. (2022). Transverse myelitis following SARS-CoV-2 vaccination: A pharmacoepidemiological study in the World Health Organization's database. *Annals of Neurology, 92*(6), 1080–1089.

Nicola, M., Alsafi, Z., Sohrabi, C., Kerwan, A., Al-Jabir, A., Iosifidis, C., et al. (2020). The socio-economic implications of the coronavirus pandemic (COVID-19): A review. *International Journal of Surgery, 78,* 185–193.

Patone, M., Handunnetthi, L., Saatci, D., Pan, J., Katikireddi, S. V., Razvi, S., et al. (2021). Neurological complications after first dose of COVID-19 vaccines and SARS-CoV-2 infection. *Nature Medicine, 27*(12), 2144–2153.

Rodríguez, Y., Rojas, M., Pacheco, Y., Acosta-Ampudia, Y., Ramírez-Santana, C., Monsalve, D. M., et al. (2018). Guillain–Barré syndrome, transverse myelitis and infectious diseases. *Cellular & Molecular Immunology, 15*(6), 547–562.

Román, G. C., Gracia, F., Torres, A., Palacios, A., Gracia, K., & Harris, D. (2021). Acute transverse myelitis (ATM): Clinical review of 43 patients with COVID-19-associated ATM and 3 post-vaccination ATM serious adverse events with the ChAdOx1 nCoV-19 vaccine (AZD1222). *Frontiers in Immunology, 12.* https://doi.org/10.3389/fimmu.2021.653786

Tahir, N., Koorapati, G., Prasad, S., Jeelani, H. M., Sherchan, R., Shrestha, J., et al. (2021). SARS-CoV-2 vaccination-induced transverse myelitis. *Cureus.* https://www.cureus.com/articles/63667-sars-cov-2-vaccination-induced-transverse-myelitis

Transverse myelitis in children and adults. (2023). *In Handbook of Clinical Neurology* (pp. 101–117). Elsevier. https://linkinghub.elsevier.com/retrieve/pii/B978032398817900020X

Van Doremalen, N., Lambe, T., Spencer, A., Belij-Rammerstorfer, S., Purushotham, J. N., Port, J. R., et al. (2020). ChAdOx1 nCoV-19 vaccination prevents SARS-CoV-2 pneumonia in rhesus macaques. *bioRxiv.* https://doi.org/10.1101/2020.05.13.093195

Wahid, M., Jawed, A., Mandal, R. K., Areeshi, M. Y., El-Shall, N. A., Mohapatra, R. K., et al. (2023). Role of available COVID-19 vaccines in reducing deaths and perspective for next generation vaccines and therapies to counter emerging viral variants: An update. *Minerva Medica, 114*(5). https://www.minervamedica.it/index2.php?show=R10Y2023N05A0683

Wilder-Smith, A., & RF, A. (2020). WHO SAGE values framework for the allocation and prioritization of COVID-19 vaccination. *World Health Organization.* https://researchonline.lshtm.ac.uk/id/eprint/4658098